




Contents lists available at ScienceDirect

## World Journal of Acupuncture – Moxibustion

journal homepage: [www.elsevier.com/locate/wjam](http://www.elsevier.com/locate/wjam)

## Clinical Report

## Effect of 43 cases of temporomandibular joint dysfunction treated with thumb-tack needle based on the meridian cutaneous region theory

Jun WANG (王军), Sheng CHEN (陈晟), Zi-Chen WANG (王子辰), Jia-jia ZHANG (张佳佳), Cheng TAN (谭程)\*

Department of Acupuncture and Moxibustion, Dongzhimen Hospital, Beijing University of Traditional Chinese Medicine, Beijing 100700, China (北京中医药大学东直门医院针灸科 中国·北京100700)

## ARTICLE INFO

## Article history:

Available online 29 August 2018

## Keywords:

Temporomandibular joint dysfunction  
Theory on the cutaneous regions of meridians  
Thumb-tack needle acupuncture therapy

## ABSTRACT

**Objective:** To observe the clinical efficacy of thumb-tack needle on temporomandibular joint dysfunction (TMD).**Methods:** A total of 43 outpatients of TMD were treated with thumb-tack needle. After the skin routine sterilization, the intradermal needles, 0.2 mm × 1.5 mm (the SEIRIN-thumb-tack needle) were embedded subcutaneously at Zúlínqì (足临泣 GB 41), Zhōngzhǔ (中渚 TE 3) and Xiàguān (下关 ST 7) on the affected side. The acupoints were pressed and kneaded gently to induce mild soreness and distention. When pressing and kneading GB 41 and TE 3, the patients were required to open and close the mouth in small amplitude to achieve the effects of kinetic acupuncture. The treatment was given twice a week. The needles were retained for 24 h. A total of 6 treatments were required.**Results:** A total of 22 cases were cured, accounting for 51.16%, 15 cases effective remarkably, accounting for 34.88% and 6 cases failed, accounting for 13.95%. The total effective rate was 86.05%.**Conclusion:** The thumb-tack needle is significantly effective on TMD.

© 2018 Published by Elsevier B.V. on behalf of World Journal of Acupuncture Moxibustion House.

Temporomandibular joint dysfunction (TMD) is the common and frequently-occurring disease in the stomatology department, with the temporomandibular joints and the muscles of mastication involved. It is the collective term of the restricted mandibular movement, pain and clicking of joint during the temporomandibular movement [1]. TMD is commonly seen in young adults, with long duration of sickness and it affects the food intake and life in the patients. Since July 2015, guided by the theory of the meridian cutaneous regions, the authors adopted the thumb-tack needle for the disease and significant therapeutic effects were obtained. The report is as follows.

## Clinical data

All of 43 patients were collected from the Department of Acupuncture and Moxibustion, Dongzhimen Hospital affiliated to Beijing University of Traditional Chinese Medicine. All of the cases were taken for the unilateral TMD. Of 43 cases, there were 23 males and 20 females, aged from 23 to 58 years, with an average

age of (33.5 ± 8.9) years old. The duration of sickness was ranged from 2 to 52 weeks, with an average week of (9.05 ± 12.18) weeks.

## Treatment methods

## Acupoint selection

Zúlínqì (足临泣 GB 41), Zhōngzhǔ (中渚 TE 3) and Xiàguān (下关 ST 7). See Fig. 1.

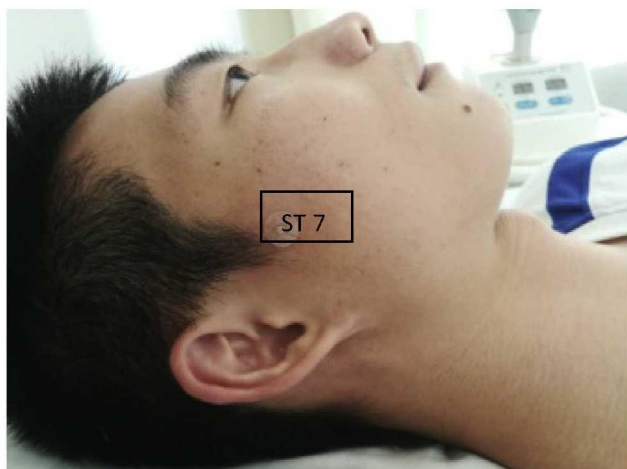
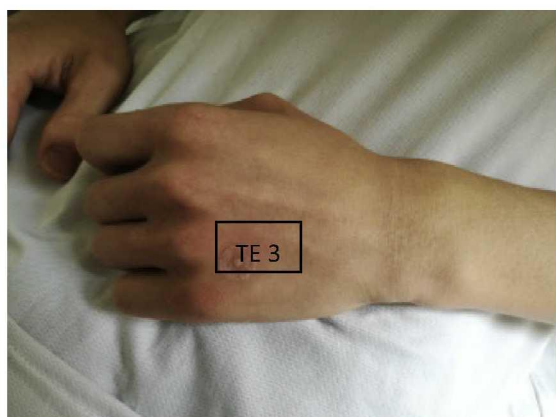
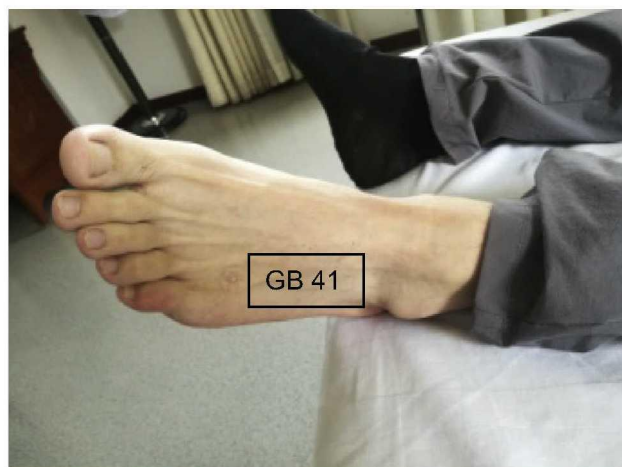## Manipulation

The patient was in sitting or supine position. After the routine sterilization of the skin on the acupoints of the affected side, the thumb-tack needles (0.2 mm × 1.5 mm, the intradermal needle for single use, SEIRIN thumb-tack needle brand, No. 17422C1) were embedded subcutaneously at GB 41, TE 3 and ST 7 on the affected side (Fig. 1). The acupoints were pressed and kneaded gently to induce mild soreness and distention. When pressing and kneading GB 41 and TE 3, the patients were required to open and close the mouth in small amplitude to achieve the effects of kinetic acupuncture. The needle-embedding sites were stimulated with

\* Corresponding author.

E-mail address: [tancheng206@126.com](mailto:tancheng206@126.com) (C. TAN).<https://doi.org/10.1016/j.wjam.2018.08.004>

1003-5257/© 2018 Published by Elsevier B.V. on behalf of World Journal of Acupuncture Moxibustion House.



**Fig. 1.** Thumb-tack needle were embedded subcutaneously at GB 41, TE 3 and ST 7 on the affected side.

pressing and kneading for 4 to 5 times during the 24 h needle retaining, 1–2 min each time. The thumb-tack needles were removed by the patients themselves on the second day.

#### Treatment courses

The treatment was given twice a week. The needles were retained for 24 h in each treatment. 6 treatments were required. After 6 treatments, the therapeutic effects were observed. During treatment, the patients were advised to avoid the raw, cold and hard food, as well as opening the mouth largely.

#### Therapeutic results

##### Cured

A total of 22 cases were cured, accounting for 51.16%, with complete disappearance of the subjective symptoms, normal temporomandibular joint movement, normal degree of mouth open, clicking of joint disappearance from the joint and recovery of masticatory function.

##### Remarkably effective

A total of 15 cases were effective remarkably, accounting for 34.88%, with basic disappearance of the subjective symptoms, nearly normal opening degree of the mouth, slightly clicking of joint from the temporomandibular movement, and discomforts when the mouth opens.

##### Ineffective

There were 6 cases of no effect, accounting for 13.95%, with no change in the subjective symptoms or aggravated symptoms as compared with that before treatment.

The total effective rate was 86.05%.

#### Discussion

The meridian cutaneous region is the important component of meridian-collateral system in human body. It is the most external layer of the body and communicates with *qi* and blood of meridian and collateral. It is the site for the *qi* distribution of the collateral. Same as the twelve meridians, the divergent meridians and the muscles regions of meridians, the meridian cutaneous region reflects disorders, protects the body and prevents from the invasion of exogenous factors [2,3]. Many disorders can be treated in the guidance of the cutaneous region theory in meridian-collateral system. The *Shaoyang* meridian runs on the lateral side of the human body. The cutaneous region of *Shaoyang* meridian is distributed in consistence with the pathway of *Shaoyang* meridian and its indications are similar to it. It is recorded in *Lingshū: Gēnjié* (《灵枢·根结》 *Miraculous Pivot: Root and Knot*) that the *Shaoyang* is taken as the pivot for the bone instability. TMD is manifested as joint movement disorder, pain and noises from the temporomandibular joint movement. The location of sickness is closely related to the running courses of the Foot-*Yangming* meridian and the foot-*Shaoyang* meridian [4]. The symptom characteristics of TMD are in compliance with the disorder recorded in the above-mentioned ancient book. Based on the theory of the meridian cutaneous region, TMD should be treated in term of the cutaneous region of the *Shaoyang* meridian. The authors selected TE3 of the hand-*Shaoyang* meridian and GB41 of the foot-*Shaoyang* meridian as the main acupoints. The combination of the upper and lower points is coincident with the treating principle of the *Shaoyang* cutaneous region theory and corresponds to the indication on the running course of meridian. Both of them are the *shu*-stream point for the body heaviness and joint pain [5]. ST 7 is located near to the temporomandibular joint, as the local acupoint selection principle. It is good at regulating the functions of the local affected meridian, activating blood circulation and stopping pain. The stimulation with the pressing and kneading at the acupoints, combined with the kinetic acupuncture improves *qi* and blood circulation in the local affected area, aiming to promote the circulation in meridian and stop pain.

The therapeutic regimen is in the guidance of the meridian cutaneous region theory and in compliance with the traditional meridian differentiation. The acupoint selection is responded to the combination of the upper and the lower points and that of

the distal and nearby points. This therapy achieves the remarkable effects and is actively significant for the clinical application of the meridian-collateral theory and the meridian cutaneous region theory.

### Supplementary materials

Supplementary material associated with this article can be found, in the online version, at doi:10.1016/j.wjam.2018.08.004.

### References

[1] Jafri MS, Farhang S, Tang RS, Desai N, Fishman PS, et al. Diagnosis and treatment of temporomandibular disorders. *Am Family Phys* 2015;91(6):378–86.

- [2] Li ZM. Brief on the holist effect of the twelve cutaneous regions of meridians. *Jilin J Chin Med* 1992(5):1–2.
- [3] Chen M. Brief application of the intradermal needling therapy based on the meridian cutaneous region theory. *Chin J Ethnomed Ethnopharmacy* 2018(8):6–7.
- [4] Lu ZL, Yang TS, Huang XW. Huang Xuanwei's experiences in acupuncture treatment for temporomandibular joint dysfunction. *Nei Mongol J Tradit Chin Med* 2005;24(6):18–19.
- [5] Xie JP, Li XH. Effects of “shu-stream points on body heaviness and joint pain”. *Mod Chin Clinical Med* 2001;8(2):6–8.

E-mail: 5333649@sohu.com  
 \*威海市科技发展计划项目:  
 2102016Y0101  
 收稿日期: 2018-04-04  
 正文见本期第218~220页。

例, 占23.3% (7/30), 无效4例, 占13.3% (4/30)。结论: 氩-氩激光针刺治疗神经性耳鸣疗效较好, 患者易于接受, 值得临床推广。  
 [关键词] 神经性耳鸣; 氩-氩激光针; 病例系列研究

## Effect of 43 cases of temporomandibular joint dysfunction treated with thumb-tack needle based on the meridian cutaneous region theory

### 基于经络皮部理论揸针治疗颞颌关节功能紊乱43例

#### ARTICLE INFO

第一作者: 王军, 教授。  
 研究方向: 针灸经典理论与临床研究。  
 E-mail: wangjune@yeah.net  
 通信作者: 谭程, 副主任医师。  
 研究方向: 过敏性疾病的临床与实验研究。  
 E-mail: tancheng206@126.com  
 收稿日期: 2018-05-20  
 正文见本期第221~223页。

#### ABSTRACT IN CHINESE

[摘要] 目的: 观察揸针治疗颞颌关节紊乱的临床疗效。方法: 对门诊就诊的43例颞颌关节紊乱患者采用揸针治疗。皮肤常规消毒后将0.2 mm×1.5 mm皮内针(揸针型)埋入患侧足临泣、中渚、下关, 嘱轻轻按揉, 使之有轻度酸胀感。按揉足临泣、中渚时, 令患者小幅度张口运动, 达到运动针法的效果。每周治疗2次, 每次留针24小时, 共治疗6次。结果: 治愈22例, 占51.16%; 显效15例, 占34.88%; 无效6例, 占13.95%。总有效率为86.05%。结论: 揸针治疗颞颌关节紊乱有显著的疗效。  
 [关键词] 颞颌关节紊乱综合征; 皮部理论; 揸针; 针灸

## Acupuncture at Tàichōng (太冲 LR 3) for dysmenorrhea

### 针刺太冲治疗痛经案

#### ARTICLE INFO

通信作者: Abdurachman, 医师。  
 研究方向: 针灸临床研究。  
 E-mail: abdurachman@fk.unair.ac.id  
 收稿日期: 2018-07-03  
 正文见本期第224~226页。

#### ABSTRACT IN CHINESE

[摘要] 应用针刺太冲穴对痛经患者进行治疗, 经过4次治疗后, 患者的恶心、偏头痛和痛经程度均减轻直至消失。至下两个月经周期, 患者未复发。笔者建议医者应用太冲来作为治疗原发性痛经的补充疗法。  
 [关键词] 针刺; 太冲; 痛经

## Prof. Gui-rong DONG's experience in treatment of prurigo nodularis with acupuncture

### 东贵荣教授针治结节性痒疹案

#### ARTICLE INFO

第一作者: 姜东耀, 在读。  
 E-mail: 895926169@qq.com  
 通信作者: 东红升, 副研究员。  
 研究方向: 针刺治疗疑难疾病临床及机理研究。  
 E-mail: dhsdoctor2005@126.com  
 收稿日期: 2018-06-30  
 正文见本期第227~228页。

#### ABSTRACT IN CHINESE

[摘要] 予结节性痒疹患者以百会、风池、风府、大椎、风门、心俞、肝俞、气海、关元、中脘、血海、足三里、三阴交、内庭、曲池、外关、合谷穴位针刺治疗, 一周四次。针刺治疗2周后自觉瘙痒程度减轻, 能够忍耐并容易入睡, 治疗2个月后, 未见新发皮疹, 并瘙痒基本消失, 陈旧性皮疹开始消退, 显示红肿颜色变淡, 凸起皮疹开始吸收变平, 治疗五个月后, 已无瘙痒症状, 皮疹基本消退, 遗留皮肤暗灰色沉着色斑, 治疗六个月后, 暗灰色沉着色斑消失, 皮肤如常。随访一年未见复发。  
 [关键词] 结节性痒疹; 针刺